

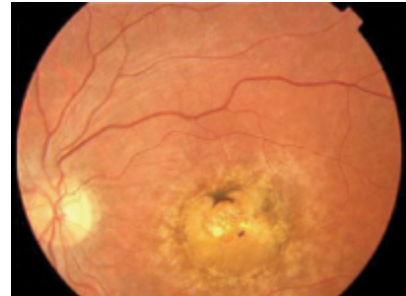
The Great Beyond

The *Nature* blog that rounds up science news from around the world

Posted by Elie Dolgin on November 19, 2009

Embryonic stem cells to cure eye disease?

Human embryonic stem cells could be one step closer to the clinic. Santa Monica, California-based Advanced Cell Technology (ACT) announced today that it has applied to US regulators to launch a new clinical trial aimed at reversing vision loss with retinal cells recreated from embryonic stem (ES) cells.



The company plans to test the stem cell-derived retinal cells in 12 patients suffering from Stargardt's disease, a form of inherited juvenile macular degeneration that affects around one in 10,000 children.

ACT researchers previously showed that ES cells could give rise to retinal pigment epithelium cells, the photoreceptors that go awry in the disease. They then demonstrated that the cells could restore vision in a rat model of retinal disease. And in September, the researchers reported that the cells were long-lasting and safe in a mouse model of Stargardt's.

"Our research clearly shows that stem cell-derived retinal cells can rescue visual function in animals that otherwise would have gone blind," said Robert Lanza, ACT's chief scientific officer, in a statement. "We are hopeful that the cells will be similarly efficacious in patients."

ACT's investigational new drug (IND) application is only the second filing with the US Food and Drug Administration for a therapy involving human ES cells. The first company out of the gate, Menlo Park, California-based Geron Corp., had its stem-cell derived therapy to treat spinal cord injury patients approved last January. But the FDA put a hold on the trial before a single patient had been injected with the cells, citing safety concerns. Geron now says it plans to restart the trial in the second half of next year.

For more on why stem cell-derived transplants could work to delay or prevent blindness, see the June 2009 news feature from the sadly now-defunct Nature Reports Stem Cells.

Image: The left eye of a Stargardt's patient from Özdek et al., *Eye* 19, 1222–1225 (2005).